



**PATIENT PRESENTING CLINICAL SIGNS**

Mia Abril History: Hematuria. Liver and gall bladder changes on previous ultrasound.

**SPECIES** Physical Examination: N/A.

Canine Urinalysis: SG 1.017, hematuria, pyuria, proteinuria. Culture pending.

CBC: Lymphopenia.

**BREED** Serum Biochemistry: Elevated creatinine, ALP activity, and potassium.

Mixed breed Radiographic Findings: N/A.

**SEX ULTRASONOGRAPHIC EXAMINATION OF THE ABDOMEN**

FS

**Urinary System**

**AGE**

12 years

Full urinary bladder with a normal thickness (0.3 cm) and appearance of the wall except for a focal irregular hyperechogenic thickening of the dorso-caudal wall (0.6 cm). Moderate amount of floating hyperechogenic sediment. No uroliths evident.

**WEIGHT**

24 #

Normal trigone area, proximal urethra, and iliac blood vessels.

Normal iliac lymph nodes (left 0.3 cm, right 0.4 cm). Ureters not visualized.

**INTERPRETED BY**

Remo Lobetti, BVSc,  
MMedVet (Med), PhD,  
Dipl. ECVIM

Normal renal size (left 5.6 cm, right 5.4 cm), echogenic appearance, cortico-medullary differentiation, and capsule. Mid bilateral pyelectasia (both 0.25 cm).

**Reproductive System**

N/A.

**IMAGING PERFORMED BY**

Dr Gabriel Ferrer, DVM

**Adrenal Glands**

Normal shape, echogenic appearance, position, and size. Left 0.57 cm, right 0.51 cm.

**HOSPITAL NAME**

Paseos Veterinary Center

**Spleen**

Normal size (1 cm) and echogenic appearance. Smooth homogenous parenchyma, regular capsule, and normal vasculature. No evidence of inflammatory, neoplastic, infarction, or infiltrative changes noted.

**REFERRING VET**

Dr Franco Ortiz

**Liver**

**INVOICE**

302968

Normal size with a diffuse mottled and nodular echogenic appearance, and some loss of portal markings. Nodules are diffuse, irregular, parenchymal, and of varying sizes (up to 1.3 x 2.1 cm) and echogenic appearance (from hypo-to-hyperechoic). Full gall bladder containing large amount of adhered and non-adhered hyperechogenic sediment in a stellate pattern. Normal thickness (0.1 cm) and echogenic appearance of the gall bladder wall. Normal bile duct.

**DATE**

5/17/22



**PATIENT** *Gastrointestinal*

Mia Abril Normal appearance of the stomach, duodenum, small intestine, ileo-cecal junction, and colon with no loss of layering, normal wall thickness (stomach 0.31 duodenum 0.56 cm, jejunum 0.41 cm, colon 0.16 cm) and peristaltic activity and no distension of the lumen. Ingesta within the stomach.

**SPECIES**

Canine *Pancreas*

**BREED**

Normal size (left 1 cm, right 1.3 cm) and echogenic appearance. Normal echogenic appearance of the mesentery and fat surrounding the pancreas.

Mixed breed

*Free Abdomen*

**SEX**

Prominent mesenteric lymph nodes (0.8 x 1.1 cm) with normal shape and echogenic appearance. No ascites.

FS

**AGE**

**ULTRASONOGRAPHIC FINDINGS**

12 years

Primary Findings:

**WEIGHT**

- Nodular hepatopathy.
- Mucocele.
- Focal urinary bladder thickening.
- Prominent mesenteric lymph nodes.

24 #

**INTERPRETED BY**

Secondary Findings:

Remo Lobetti, BVSc,  
MMedVet (Med), PhD,  
Dipl. ECVIM

- Urinary bladder sediment.
- Bilateral pyelectasia.

**IMAGING PERFORMED BY**

**INTERPRETATION OF THE FINDINGS & FURTHER RECOMMENDATIONS**

Dr Gabriel Ferrer, DVM

Etiologies for the nodular hepatopathy would be hyperplasia, nodular regeneration, chronic hepatitis, granulomatous disease, and neoplasia.

**HOSPITAL NAME**

The appearance of the gall bladder is typical for a mucocele.

Paseos Veterinary Center

Etiologies for the focal thickening of the urinary bladder wall would be chronic cystitis, granulomatous reaction, and emerging neoplasia.

**REFERRING VET**

The most likely etiology for the mesenteric lymphadenomegaly would be reactive with lymphadenitis and infiltrative neoplasia unlikely diagnoses.

Dr Franco Ortiz

Although the pyelectasia may be an incidental finding, emerging pyelonephritis should be considered.

**INVOICE**

Etiologies for the urinary bladder sediment would be hemorrhage, bacterial cystitis, and crystalluria.

302968

**DATE**

Further assessment would be 3-view thoracic radiographs, catheter-assisted biopsy, and FNA cytology of the liver.

5/17/22

Specific therapy would be dependent on an etiological diagnosis. Symptomatic therapy of the liver and gall bladder would be ursodiol.



**PATIENT IMAGES**

Mia Abril **Liver**

**SPECIES**

Canine

**BREED**

Mixed breed

**SEX**

FS

**AGE**

12 years

**WEIGHT**

24 #

**INTERPRETED BY**

Remo Lobetti, BVSc,  
MMedVet (Med), PhD,  
Dipl. ECVIM

**IMAGING PERFORMED BY**

Dr Gabriel Ferrer, DVM

**HOSPITAL NAME**

Paseos Veterinary Center

**REFERRING VET**

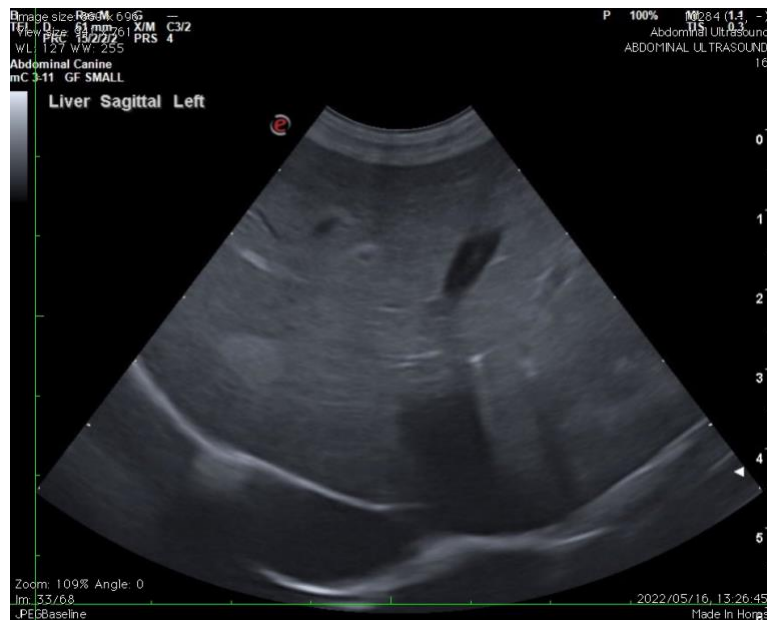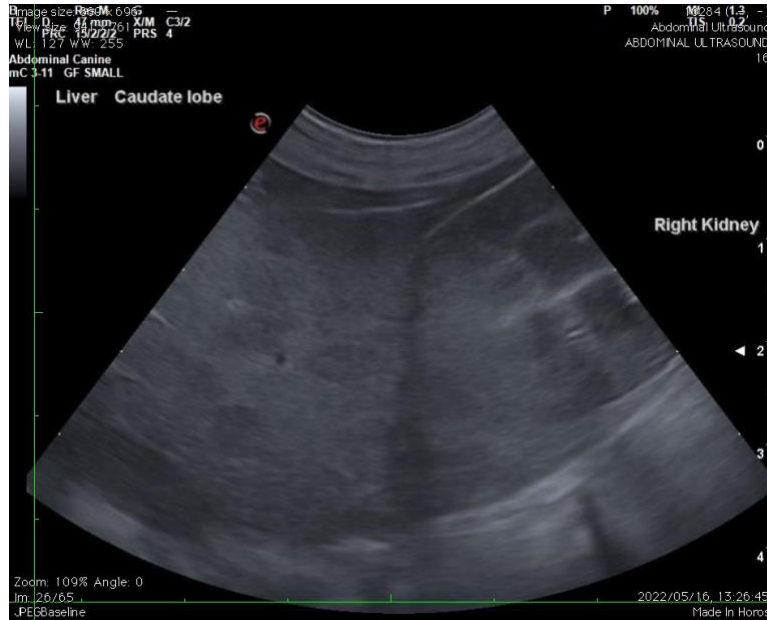
Dr Franco Ortiz

**INVOICE**

302968

**DATE**

5/17/22





**PATIENT** Gall bladder

Mia Abril

**SPECIES**

Canine

**BREED**

Mixed breed

**SEX**

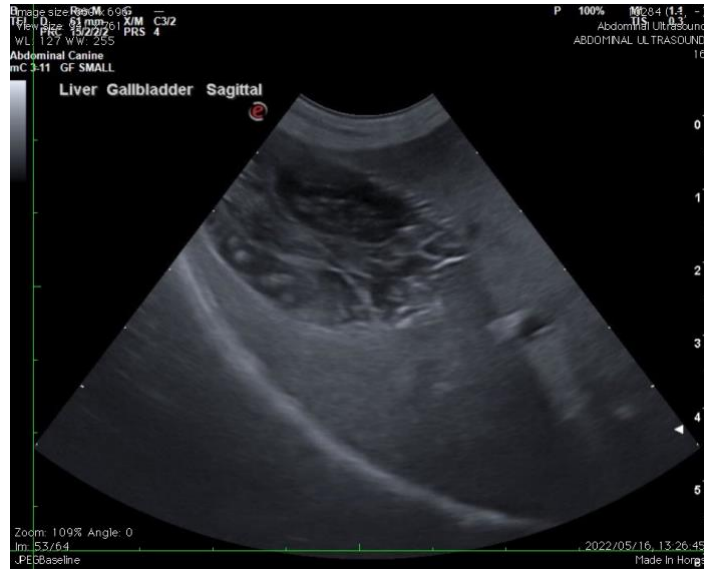FS

**AGE**

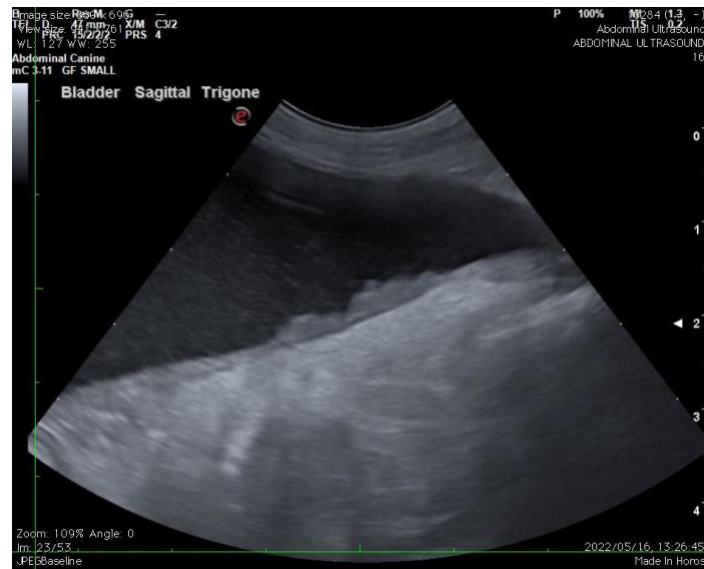12 years

**WEIGHT**

24 #



**Urinary bladder**



**INTERPRETED BY**

Remo Lobetti, BVSc,  
MMedVet (Med), PhD,  
Dipl. ECVIM

**IMAGING PERFORMED BY**

Dr Gabriel Ferrer, DVM

**HOSPITAL NAME**

Paseos Veterinary Center

**REFERRING VET**

Dr Franco Ortiz

**INVOICE**

302968

**DATE**

5/17/22

The information and recommendations provided are based on the images presented by the referring veterinarian. No evaluation can be communicated regarding pathology that was not visible in the image/video clips provided.

Thank you for this referral. If the clinical or image interpretation does not parallel your findings or if I can be of any further assistance, please contact me.

**Remo Lobetti, BVSc, MMedVet (Med), PhD, Dipl. ECVIM (Internal Medicine)**  
[rlobetti@mweb.co.za](mailto:rlobetti@mweb.co.za)